

**JOURNAL OF**

# **WILDLIFE DISEASES**



## **INCIDENCE OF PIGMENTED SKIN TUMORS IN A POPULATION OF WILD MONTSENY BROOK NEWT (*CALOTRITON ARNOLDI*)**

**Albert Martínez-Silvestre,<sup>1,5</sup> Fèlix Amat,<sup>2</sup> Ferran Bargalló,<sup>3</sup> and Salvador Carranza<sup>4</sup>**

<sup>1</sup> CRARC (Catalonia Reptile and Amphibian Rehabilitation Centre), Santa Clara s/n, 08783 Masquefa, Barcelona, Spain

<sup>2</sup> Àrea d'Herpetologia, Museu de Granollers – Ciències Naturals, Francesc Macià 51, 08400, Granollers, Barcelona, Spain

<sup>3</sup> Hospital Zoològic Badalona, 08912, Conquesta, 74, Badalona, Barcelona, Spain

<sup>4</sup> Institute of Evolutionary Biology (CSIC-UPF), Passeig Marítim de la Barceloneta, 37-49 08003 Barcelona, Spain

<sup>5</sup> Corresponding author (email: Crarc\_comam@hotmail.com)

## INCIDENCE OF PIGMENTED SKIN TUMORS IN A POPULATION OF WILD MONTSENY BROOK NEWT (*CALOTRITON ARNOLDI*)

Albert Martínez-Silvestre,<sup>1,5</sup> Fèlix Amat,<sup>2</sup> Ferran Bargalló,<sup>3</sup> and Salvador Carranza<sup>4</sup>

<sup>1</sup> CRARC (Catalonia Reptile and Amphibian Rehabilitation Centre), Santa Clara s/n, 08783 Masquefa, Barcelona, Spain

<sup>2</sup> Àrea d'Herpetologia, Museu de Granollers – Ciències Naturals, Francesc Macià 51, 08400, Granollers, Barcelona, Spain

<sup>3</sup> Hospital Zoològic Badalona, 08912, Conquesta, 74, Badalona, Barcelona, Spain

<sup>4</sup> Institute of Evolutionary Biology (CSIC-UPF), Passeig Marítim de la Barceloneta, 37-49 08003 Barcelona, Spain

<sup>5</sup> Corresponding author (email: Crarc\_comam@hotmail.com)

**ABSTRACT:** We report the presence of pigmented skin tumors in three populations of the endangered amphibian Montseny brook newt, *Calotriton arnoldi*, one of the European amphibian species with the smallest distribution range (40 km<sup>2</sup> in the Montseny Natural Park, Catalonia, Spain). Examination of one of the tumors by light microscopy was consistent with chromatophoroma and was most suggestive of a melanophoroma. Tumors were not found in juveniles. In adults, only two of three populations were affected. The proportions of males and females affected were not significantly different, but there was a positive correlation between body size and presence of tumors in both sexes. The etiology of chromatophoromas remains unknown but, in our study, they do not appear to have been caused by water quality or Ultraviolet B.

**Key words:** *Calotriton arnoldi*, chromatophoroma, dermatology, emergent diseases, melanocytoma.

### INTRODUCTION

Many factors negatively impact amphibians worldwide including habitat modification and loss, environmental contamination, climate change, infectious diseases, commercial exploitation, and invasive species (Crump, 2009). How these factors present within the population may vary but, in some cases (e.g., exposure to certain contaminants, changes in temperatures, various pathogens), may result in skin abnormalities including neoplasia. Skin neoplasms have been reported rarely in amphibian field surveys (Khudoley and Mizgireuv, 1980) and are usually attributed to environmental degradation of streams, increase in temperature, or chromosomal alterations (Zavanella and Arias, 1982; Zavanella, 1985; Wheeler et al., 2002; Miller and Miller, 2005). Most spontaneous skin neoplasms in newts have been described from captive populations (Kousoulakos et al., 1994).

The Montseny brook newt (*Calotriton arnoldi*) was described by Carranza and Amat (2005). It is restricted to a geographic area of <40 km<sup>2</sup> within the Montseny mountain massif (North Eastern

Iberian Peninsula). Despite significant efforts over the last 5 yr to find more, only seven populations are currently known. The total number of adults has been estimated at less than 1,500 individuals. These newts are entirely aquatic and live in fast-flowing streams in forested areas at altitudes between 620 and 1,200 m (Amat and Carranza, 2006). Based on its extremely small range and population size, *Calotriton arnoldi* is considered an endangered species (Carranza, 2008). The demography, activity, genetics, and morphology of some populations are being investigated to increase our knowledge of the species and to plan appropriate conservation measures. The spread of emergent diseases is becoming a serious threat to amphibian conservation worldwide, especially in extremely endangered species such as *Calotriton arnoldi*. Part of the recovery plan (Carranza, 2008) is to investigate the existence of diseases in this species and, if found, to characterize them and analyze their population incidence.

### MATERIALS AND METHODS

Our study was performed with wild newts examined from populations at three sites,

referred to herein as populations one, two, and three. Population one inhabits a small stream in a beech forest at 1,200 m on a south-facing mountain slope. Population two is found in a tiny stream inside a mixed forest of oak and alder at 800 m in a north-facing valley that experiences severe summer drought. Population three is near the second population and is, therefore, at approximately the same altitude and in the same habitat. However, the stream where the newts live is wider and deeper than the stream from population two. All of these streams are located at 41°45'29"N, 2°25'46"E.

Sampling was conducted at night, in spring and autumn, and included 21, five, and 19 visits to populations one, two, and three, respectively, during 2006–2008. We caught newts by hand, determined their sex using secondary sexual characters (morphology of the cloacal area and tail height), measured snout-vent length (SVL), and marked them using Visible Implant Elastomers (VIE; Northwest Marine Technology, Inc., Seattle, Washington, USA). Newts were visually examined for body abnormalities (supranumerary legs or digits, scoliosis, or double tail) and their numbers and body positions were recorded. One of the most-affected individuals was captured and euthanized with phenobarbital (100 mg/kg intracoelomic) for a complete pathologic study. Samples of approximately 10 × 5 × 5 mm of skin and internal organs (esophagus, stomach, intestine, liver, gall bladder, spleen, pancreas, adipose tissue, striated muscle, brain, spinal cord, spinal nerve, ganglia, kidney, ureter, testis (active), epididymis, deferent duct, bones [vertebrae, skull, full posterior limb], heart, arteries, cloaca, oropharynx, ear, nasal cavity, trachea, and lung) were removed. Tissues were fixed in neutral-buffered 10% formalin, embedded in paraffin, sectioned at 5 µm for light microscopy, and stained with hematoxylin and eosin for histopathologic examination.

Data were analyzed using conventional parametric statistics after log transformation of continuous variables. We used analysis of variance (ANOVA) to evaluate differences in body size among normal specimens and in newts with nodules. We investigated the relationship between body size and number of skin nodules using a Pearson parametric correlation. A chi-square test was used to test differences in the incidence of body abnormalities between age classes (adults versus juveniles) and sexes. We also used this test to infer the co-occurrence of different kinds of body abnormalities.

TABLE 1. Sample size of examined Montseny brook newts (*Calotriton arnoldi*) collected from Montseny Natural Park, Catalonia, Spain, by population and age class.

Population	Adults	Juveniles	Total
One	98	9	107
Two	33	13	46
Three	50	0	50
Total	181	22	203

## RESULTS

We examined 203 newts (181 adults and 22 juveniles) from the three populations (Table 1). Macroscopically, skin lesions were intense, black, solitary, circumscribed, and irregularly defined nodules with a diameter of 1–4 mm (Fig. 1). Histologic examinations of samples from the euthanized newt confirmed that the skin formations were nonencapsulated chromatophoromas resulting from proliferation of cells containing black-brown pigment. Although not confirmed by electron microscopy or special histochemical or immunohistochemical techniques, this pigment was consistent with melanin (Fig. 2). The tumor was restricted to the dermis and did not invade the underlying lymph sacs or internal organs, thus suggesting it was benign. Because histopathologic results and biologic behavior suggested a benign mass, these skin nodules were considered melanocytomas. The nodes were restricted to the dermal and epidermal area and were limited to the dermis; invasion of underlying lymph sacs was not observed and the cellular proliferations did not affect internal organs or body structures. In field surveys, 27% (29 individuals) of the newts were affected by skin tumors in population one. In population two, only one individual, an adult male, had skin tumors (2%) and no affected specimens were found in population three. No skin tumors were found in juvenile newts.

Adults in population one were significantly more affected than juveniles (adult

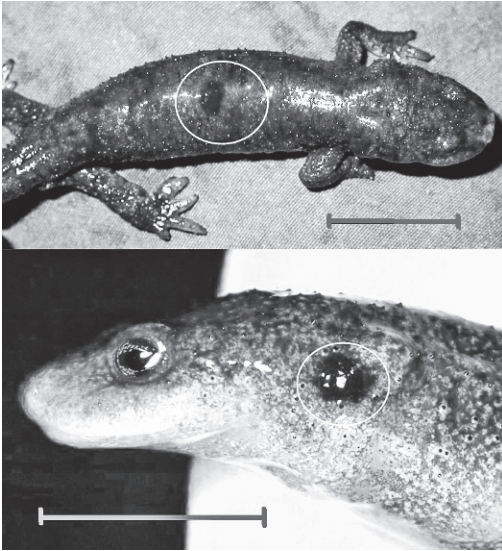


FIGURE 1. Photographs of Montseny brook newts (*Calotriton arnoldi*) collected from Montseny Natural Park, Catalonia, Spain showing pigmented masses consistent with chromatophoromas (circled areas). Bar=1 cm.

prevalence=31%). We did not find differences in the prevalence of skin tumors between sexes (chi-square=0.018; df=1;  $P=0.893$ ).

The mean ( $\pm$ SE) number of skin tumors per affected newt was  $2.3 \pm 0.3$  (range 1–10). Tumors were present more frequently on the back and flanks than on other body areas (Table 2). Body size was positively correlated with the number of skin tumors ( $r=0.224$ ;  $P=0.026$ ;  $n=30$ ). Mean SVL in affected adult newts ( $61.3 \pm 0.4$ ; range 56–67) was significantly larger than in unaffected individuals ( $59.3 \pm 0.3$ ; range 53–65; ANOVA,  $F_{1,96}=11.977$ ;  $P<0.001$ ).

#### DISCUSSION

We report the occurrence of pigmented skin tumors in three wild populations of the Montseny brook newt (*Calotriton arnoldi*). The tumor examined by light microscopy was consistent with a chromatophoroma and most suggestive of a melanophoroma. The morphology of the tumor was consistent with observations that it was a benign

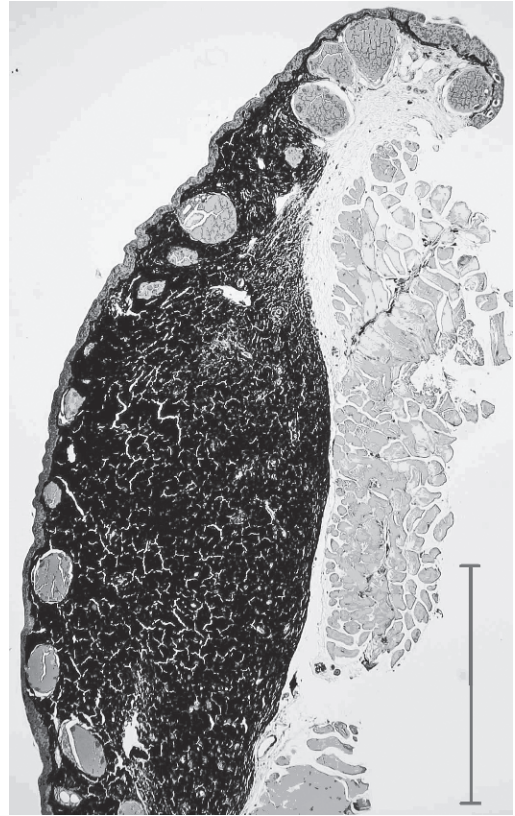


FIGURE 2. Section of a pigmented skin mass collected from a Montseny brook newt (*Calotriton arnoldi*) collected from Montseny Natural Park, Catalonia, Spain. The pigment was most consistent with melanin. The mass was well-demarcated, confined to the dermis, and most suggestive of a benign mass. Hematoxylin and eosin stain. Bar=1 mm.

mass. However, we do not know if all of the pigmented skin tumors in the wild Montseny brook newts we examined were melanophoromas, nor do we know if malignant pigmented tumors occur in this species. The absence of skin tumors in immature newts, the correlation between SVL and the number of skin tumors, and the larger body size of affected newts suggest a progressive development of pigmented skin tumors throughout an individual's life. A similar pattern was observed in Mexican axolotls (*Ambystoma mexicanum*), which showed a high correlation between age and the presence of melanophoromas (Khudoley and Mizgireu, 1980). In that

TABLE 2. Descriptive statistics (mean  $\pm$  standard error and range) of the numbers of chromatophoromas by body area and number of affected individuals (n=30) of Montseny brook newts (*Calotriton arnoldi*) collected from Montseny Natural Park, Catalonia, Spain.

Body area	No. of affected newts	Tumors per individual (mean $\pm$ SE)	Range
Head	1	1	
Back	16	1.9 $\pm$ 0.17	1–3
Flanks	16	1.3 $\pm$ 0.19	1–4
Venter	7	1.4 $\pm$ 0.20	1–2
Limbs	2	1.5 $\pm$ 0.50	1–2
Tail	4	3.2 $\pm$ 0.75	2–5

study, axolotls developed proliferation of melanophores as a nodular growth (as in our case) at 2.5 mo of age and developed additional masses 16 mo later. However, the authors could not correlate the presence of chromatophoromas with body size, hereditary predisposition, or other physical causes.

A thorough analysis of water quality for all seven streams where the Montseny brook newt occurs was carried out to check for any traces of metal and positive or negative ions (F. Amat and S. Carranza, unpubl. data). The analyses showed no traces of water pollution (chemical or biological), and water composition (dissolved solids, mineral contents, pH, etc.) did not differ between the stream inhabited by the significantly affected population and the other two, geographically close populations that were unaffected by chromatophoromas. Although some chemicals, particularly the fungicide manganese ethylenebisdithiocarbamate (maneb), have been reported as a cause of pigmented skin tumors in captive European newts (*Triturus cristatus*; Zavanella et al., 1980), no data are available about this compound in our study area. Population one from our study had a relatively high mitochondrial DNA variability of cytochrome b in comparison to the other populations (Carranza and Amat, 2005), indicating that endogamy was not a cause for the pigmented skin tumors in population one.

Another possible cause for the tumors is ultraviolet-B (UV-B) radiation. We found significantly more pigmented skin tumors on the dorsum than on the ventrum of the newts. Both body areas have approximately the same surface area, but only the dorsum is exposed to sunlight. Nevertheless, the dorsum of this species is heavily pigmented and, hence, has a higher density of chromophores than the translucent ventrum, thereby favoring the development of pigmented tumors in this area. Nevertheless, newts are aquatic and largely nocturnal stream dwellers, and the stream inhabited by this population is protected in summer, when solar radiation is more intense, by a dense cover of beech trees. These conditions would make the UV-B hypothesis seem less likely.

As a consequence of climate change, the Montseny massif has experienced a rise in environmental temperatures that has affected the altitudinal succession of forest or butterfly communities (Peñuelas and Boada, 2003; Stefanescu et al., 2004). During the last century, its forests were heavily exploited to make charcoal and to make space for cultivation. As a result, the landscape of the Montseny mountain massif consisted of a mosaic of small patches of forest, farms, and pastures (Boada, 1994). In the last 50 yr, however, the abandonment of traditional agricultural and forest exploitation has resulted in a vigorous expansion of forests, and watercourses have become drier as a result of the increased level of plant transpiration and the rise in temperature (Peñuelas and Boada, 2003). All the streams where the Montseny brook newt populations occur are affected by severe droughts in summer and winter. During these periods, the newts migrate into the rock crevices, where a subterranean cold watercourse provides good conditions for survival. However, adult newts are active in the stream when both climatic and hydrologic conditions are favorable (spring and autumn), whereas juveniles are rarely observed in the outer stream and pass most

of their life among the rocks. The lack of pigmented skin tumors in juveniles suggests that the agent responsible for these pathologies may be present in the upper stream, where it progressively affects adults during their lifetime. Skeletochronologic studies have indicated that there is a correlation between body size and age in salamanders (Ash et al., 2003). If this also holds true for *Calotriton arnoldi*, the larger newts are also the oldest and, therefore, should be more affected by this external agent. This was corroborated by the positive correlation between nodule numbers and SVL in our study.

In addition to UV-B radiation, other external causes may include the progressive rise in temperature that has affected the stream surface as a result of environmental changes in the Montseny mountain massif. It is also possible that the incidence of age-associated pigmented skin tumors is due to cumulative sun exposure of adult newts over time. Indeed, studies of chromatophoromas of crested newts (*Triturus cristatus*) have indicated a temperature-dependent growth rate for the tumors (Zavanella, 1985). Long-term monitoring of environmental and water temperatures in the streams inhabited by this endangered species may further elucidate the causes of this pathology.

#### ACKNOWLEDGMENTS

We are grateful to the Diputació de Barcelona (Natural Park of Montseny) and the Generalitat de Catalunya (Departament de Medi Ambient) for financial and logistic support to our investigation of the biology and pathology of *Calotriton arnoldi*. We thank Josep Roca and Joaquim Soler for their valuable comments on this manuscript.

#### LITERATURE CITED

- AMAT, F., AND S. CARRANZA. 2006. Aproximació a l'evolució i biologia del tritó del Montseny. *Calotriton arnoldi* (Amphibia, Salamandridae). Conservació d'una raresa amagada i singular. Monografies del Montseny 21: 165–191.
- ASH, A. N., R. C. BRUCE, J. CASTANET, AND H. FRANCILLON-VIELLOT. 2003. Population parameters of *Plethodon metcalfi* on a 10-year-old clearcut and in nearby forest in the southern Blue Ridge Mountains. *Journal of Herpetology* 37: 445–452.
- BOADA, M. 1994. Montseny, medi i home. Fundació Rectoria Vella. ICE. Barcelona, Fundació La Caixa. pp. 56.
- CARRANZA, S. 2008. *Calotriton arnoldi*. In International Union for the Conservation of Nature (IUCN) 2008. 2008 IUCN Red List of Threatened Species, 18 January 2008, Version 2010.4, www.iucnredlist.org. Accessed January 2011.
- , AND F. AMAT. 2005. Taxonomy, biogeography and evolution of *Euproctus* (Amphibia: Salamandridae), with the resurrection of the genus *Calotriton* and the description of a new endemic species from the Iberian Peninsula. *Zoological Journal of the Linnean Society* 145: 555–582.
- CRUMP, M. L. 2009. Amphibian diversity and life history. In *Amphibian ecology and conservation. A handbook of techniques*, K. Dodd (ed.). Oxford University Press, New York, New York. pp. 3–19.
- KHUDOLEY, V. V., AND I. V. MIZGIREUV. 1980. On spontaneous skin tumours in Amphibia. *Neoplasma* 27: 289–293.
- KOUSSOULAKOS, S., M. LELOUDA, AND H. J. ANTON. 1994. Allografting of a nontransmissible, spontaneous dermal melanoma in the newt *Triturus cristatus*. *Tumor Biology* 15: 141–146.
- MILLER, B. T., AND J. L. MILLER. 2005. Prevalence of physical abnormalities in eastern hellbender (*Cryptobranchus alleganiensis alleganiensis*) populations of Middle Tennessee. *Southeastern Naturalist* 4: 513–520.
- PEÑUELAS, J., AND M. BOADA. 2003. A global change-induced biome shift in the Montseny mountains (NE Spain). *Global Change Biology* 9: 131–140.
- STEFANESCU, C., S. HERRANDO, AND F. PÁRAMO. 2004. Butterfly species richness in the north-west Mediterranean Basin: The role of natural and human-induced factors. *Journal of Biogeography* 31: 905–915.
- WHEELER, V. A., M. I. MCCALLUM, AND S. E. TRAUTH. 2002. Abnormalities in the Ozark hellbender, *Cryptobranchus alleganiensis bishopi*. *Journal of the Arkansas Academy of Science* 56: 250–252.
- ZAVANELLA, T. 1985. Environmental temperature and metastatic spread of melanoma in the crested newt. *Cancer Letters* 27: 171–179.
- , AND E. ARIAS. 1982. Chromosome variation in two populations of the crested newt, *Triturus cristatus carnifex*, with different melanoma incidence. *Cytobios* 34: 75–82.
- , N. P. ZAFFARONI, AND E. ARIAS. 1980. Testing of the fungicide maneb for carcinogenicity in two populations of the European crested newt. *Cancer Letters* 10: 109–116.

Submitted for publication 11 January 2010.

Accepted 20 December 2010.